

The Role of Ultrasonography in the Discrimination of Reactive Lymphadenopathy in Children

Çocuklarda Reaktif Lenfadenopati Ayırımında Ultrasonografinin Rolü

Elif Şeker Ekici* (0000-0002-2975-6616), Mustafa Büyükavcı** (0000-0002-9054-3134),
Yasemin Gündüz*** (0000-0002-8373-4792), Mehmet Fatih Orhan** (0000-0001-8081-6760), Bahri Elmas* (0000-0001-9034-6109)

*Sakarya University Training and Research Hospital, Clinic of Pediatrics, Sakarya, Turkey

**Sakarya University Training and Research Hospital, Clinic of Pediatrics, Division of Hematology and Oncology, Sakarya, Turkey

***Sakarya University Training and Research Hospital, Clinic of Radiology, Sakarya, Turkey



Abstract

Introduction: Many studies have been conducted on the role of ultrasonography in differentiating benign diseases that cause lymphadenopathy (LAP) from malignant diseases. However, there are no studies to distinguish LAP due to reactive etiologies from other benign infectious causes. In this study, the role of ultrasonography in the differentiation of benign LAPs was examined.

Materials and Methods: This study prospectively evaluated 165 children with LAP aged 0-18 years. According to their clinical features, benign LAPs were grouped into viral and bacterial lymphadenitis, and reactive LAPs. Ultrasonographic characteristics of each group were assessed.

Results: While loss of hilar echogenicity from ultrasonographic findings of LAPs was significant in differentiating reactive LAP from viral lymphadenitis, border irregularity was more favorable for bacterial lymphadenitis.

Conclusion: Differentiating benign LAPs is important in the decision to prescribe antibiotics. In addition to the clinical features, ultrasonographic features can also be used to make this distinction.

Keywords

Hilar echogenicity, lymphadenitis,
peripheral lymphadenopathy,
ultrasonography, reactive hyperplasia

Anahtar kelimeler

Hiler ekojenite, lenfadenit, periferik
lenfadenopati, ultrasonografi, reaktif
hiperplazi

Received/Geliş Tarihi : 26.03.2023

Accepted/Kabul Tarihi : 14.01.2024

DOI:10.4274/jcp.2024.81567

Address for Correspondence/Yazışma Adresi:

Elif Şeker Ekici, Sakarya University Training
and Research Hospital, Clinic of Pediatrics,
Sakarya, Turkey

Phone: +90 535 573 61 86

E-mail: elifseker@sakarya.edu.tr

Öz

Giriş: Lenfadenopatiye (LAP) neden olan benign ve malign hastalıkların ayırımında ultrasonografinin rolü üzerine birçok çalışma yapılmıştır. Ancak reaktif etiyojilere bağlı LAP'ı diğer benign enfeksiyöz nedenlerden ayırmaya yönelik çalışmalar yetersizdir. Bu çalışmada benign LAP'ların ayırımında ultrasonografinin rolü incelenmiştir.

Gereç ve Yöntem: Bu çalışmada LAP'lı 0-18 yaş grubu 165 çocuk prospektif olarak değerlendirildi. Klinik özelliklerine göre benign LAP'lar viral ve bakteriyel lenfadenit ve reaktif LAP'ler olarak gruplandırıldı. Her grubun ultrasonografik özellikleri değerlendirildi.

Bulgular: LAP'ların ultrasonografik bulgularından hiler ekojenite kaybı, reaktif LAP'ı viral lenfadenitten ayırmada anlamlı iken, sınır düzensizliği bakteriyel lenfadenit için daha anlamlıydı.

Sonuç: Benign LAP'ların ayırt edilmesi antibiyotik reçete etme kararında önemlidir. Bu ayırımı yapmak için klinik özelliklerin yanı sıra ultrasonografik özelliklerden de yararlanılabilir.

Introduction

Peripheral lymphadenopathy is one of the most common symptoms in childhood. Although the underlying cause is infection most often, malignancy must also be excluded. Although anamnesis and physical examination provide essential information for the differential diagnosis of diseases that cause lymphadenopathy, laboratory studies and imaging methods are often used in many cases. Ultrasonography is the preferred imaging method for children because of its low cost, accessibility, lack of radiation risk, and lack of anesthesia. Since the diagnosis of malignant diseases such as underlying leukemia and lymphoma is critical, many studies have evaluated the role of ultrasonography in the differentiation of malignant and benign causes of lymph node enlargement (1-5). However, there are few studies on the role of ultrasonography in the differentiation between lymphadenopathy with benign and reactive etiologies (6-8).

Infections and reactive hyperplasia are the most common benign events that can progress to peripheral lymphadenopathy in children (2,5,6,9,10). In daily practice, empirical antibiotic therapy is prescribed for possible infections for up to four weeks in many patients who cannot be diagnosed despite clinical findings, laboratory tests, and imaging, including ultrasonography, for differential diagnosis (11,12). If lymphadenopathy due to reactive hyperplasia, which is known to have no benefit from antibiotics, can be recognized on the first admission, vital resources will be preserved. Moreover, in some cases, the lymph node does not shrink despite antibiotic treatment, and other imaging methods, such as PET-CT, are requested, or a biopsy is performed to rule out malignancy. In this study, we compared the ultrasonographic features of reactive lymphadenopathy with those of bacterial and viral lymphadenitis, which are common benign etiologies in childhood.

Material and Methods

This prospective study included 165 children aged up to 18 years who were admitted to the Sakarya University Faculty of Medicine Training and Research Hospital, Pediatric Hematology and Oncology Outpatient Clinic between January 1, 2019, and January 6, 2020, with the complaint of peripheral lymphadenopathy. Anamnesis, physical examination,

laboratory examination, and simultaneous ultrasonographic findings were recorded. Informed consent was obtained from the patients before enrollment in the study.

On admission, complete blood count, C-reactive protein (CRP), erythrocyte sedimentation rate (ESR), uric acid, lactate dehydrogenase (LDH), and peripheral blood smear were evaluated. Empirical oral antibiotic therapy (amoxicillin-clavulanic acid-50 mg/kg/day) was initiated for patients whose etiology could not be determined. If the etiology could not be determined after 15 days of follow-up and there was no reduction in LAP sizes, serological tests (EBV VCA IgM, CMV IgM, Toxoplasma IgM, Rose Bengal, Brucella IgM, monostest, tularemia), PPD test, and chest radiography were performed. Lymph node biopsy was performed in the presence of risk findings for malignancy or in patients who could not be diagnosed using other methods. The cases were classified according to the following definitions.

1. *Viral lymphadenitis*: Cases a) who were serologically diagnosed with a viral infection and/or b) who had upper respiratory tract infection findings such as a runny nose, sore throat, and cough on physical examination and were thought to have viral infection, and c) who had upper respiratory tract infection symptoms that did not respond to antibiotics and whose lymph node sizes decreased with the regression of infection.

2. *Bacterial lymphadenitis*: Cases with painful findings such as redness and increased skin temperature on physical examination or group A beta-hemolytic streptococci (GAS) growth in throat cultures.

3. *Reactive lymphadenopathy*: In cases with no physical examination findings other than lymphadenopathy,

a. The etiology could not be determined after the first and secondary evaluations and, the lymph node size did not change with antibiotic treatment.

b. Reactive hyperplasia was diagnosed by biopsy.

Fifty-two of 165 (31.5%) ultrasonography (USG) procedures were performed by a single radiologist. In these cases, the following parameters were evaluated: Lymph node diameter, cortical thickening, cortical echogenicity, loss of hilar echogenicity, vascular pattern, contour lobulation, round or oval shape, and presence of regular or irregular borders. Different

radiologists performed other USG procedures during routine examinations.

Statistical Analysis

The data were evaluated using SPSS (Statistical Package for the Social Sciences) 26.0, software program for Windows. Continuous variables were expressed as means and standard deviations. Chi-square and Fisher's exact chi-square tests were used to compare categorical data. For numerical data, a t test and one-way ANOVA were performed for those that fit the normal distribution feature, and Mann-Whitney U and Kruskal-Wallis tests were performed for those that did not fit. The groups were compared among themselves in pairs with post-hoc tests. Statistical significance was set at $p < 0.05$.

Ethics committee approval was obtained from Sakarya University, numbered E-71522473-050.01.04-155155-227. Written informed consent was obtained from the parents of each participant.

Results

One hundred and eleven of 165 children (67.3%) were boys and 54 (32.7%) were girls, with a median age of 65 months (minimum 6, months; maximum, 213 months). A total of 141 (86%) patients presented with LAP only in the head and neck region. Eighty-four (51.5%) patients were diagnosed with viral lymphadenitis, 53 (31.5%) with reactive LAP, and 13 (8%) with bacterial lymphadenitis. The remaining 15 patients were not evaluated because they were diagnosed with cat-scratch disease, nontuberculous mycobacterial lymphadenitis, BCG lymphadenitis, Hodgkin's lymphoma, soft tissue sarcoma, and acute leukemia (Figure 1 and Table 1).

There were no significant differences between the groups in terms of lymph node size. However, the rate of hilar echogenicity loss in the viral lymphadenitis group was higher than that in the reactive LAP group. Although the irregularity of the lymph node borders was more prominent in the bacterial lymphadenitis group, there was no difference between the reactive

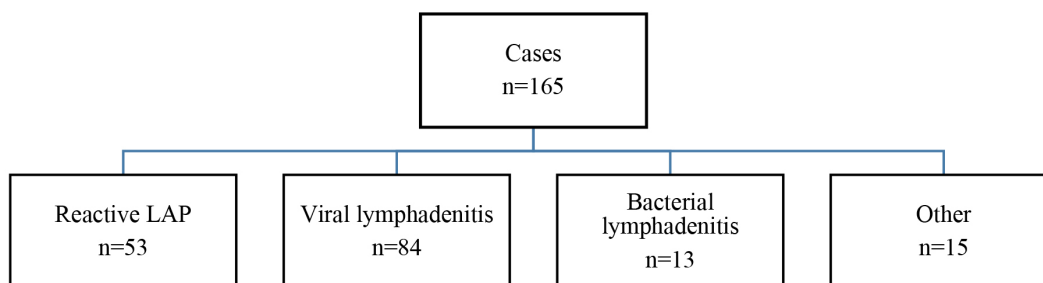


Figure 1. Patients in study groups

	n	%
Reactive LAP	53	31,5
Bacterial lymphadenitis	13	8,0
Viral lymphadenitis	84	51,5
Cat-scratch disease	6	3,6
Lymphoproliferative disease	1	0,6
Nontuberculous mycobacterial lymphadenitis	2	1,2
BCG lymphadenitis	2	1,2
Hodgkin's lymphoma	2	1,2
Soft tissue sarcoma	1	0,6
AML	1	0,6

LAP: Lymphadenopathy, AML: Acute myeloblastic leukemia

Table 2. Ultrasonography findings of viral, bacterial lymphadenitis, and reactive lymphadenopathy

	Reactive LAP n:53	Viral Lymphadenitis n:84	Bacterial Lymphadenitis n:13	p-value
Diameter of LAP	21±6.3 mm	23.1±7.2 mm	21.8±5.5 mm	0.271
Loss of hilar echogenicity (yes/no)	7/34	26/52	6/9	0.007 ¹
(%)	(20.6)	(50)	(66.7)	
Cortical thickening	21/24	41/42	5/5	0.196
(%)	(87.5)	(97.6)	(100)	
Borders (Regular/irregular)	10/0	35/1	3/2	0.003 ^{2,3}
(%)	(100/0)	(98/2)	(60/40)	
Vascular pattern (Hilar/necrotic/ peripheral)	12/0/0	35/1/0	3/1/0	0.066
(%)	(100/0/0)	(97/3/0)	(75/25/0)	

¹: A significant difference was detected between reactive LAP and viral lymphadenitis groups
²: A significant difference was detected between bacterial lymphadenitis and reactive LAP groups
³: A significant difference was detected between bacterial lymphadenitis and viral lymphadenitis groups
LAP: Lymphadenopathy

LAP and viral lymphadenitis groups. There was no significant difference between the groups in terms of the vascular pattern and cortical thickening of the lymph nodes (Table 2).

Findings (cortical thickening, increase in A-P diameter, and loss of hilar echogenicity) were evaluated using multivariate logistic regression analysis. However, none was a risk factor for reactive LAP or viral lymphadenitis.

Discussion

It is important to diagnose lymphadenopathy quickly and initiate treatment accordingly. Unnecessary examinations may lead to delays in diagnosis. Ultrasonography is highly useful for clinicians for the diagnosis of lymphadenopathy. It is non-invasive, does not contain ionizing radiation, does not require sedation, and can be applied quickly and easily. Therefore, it is frequently preferred as the first imaging method for differential diagnosis and follow-up of peripheral lymphadenopathies (6,13). Ultrasonography should be the first imaging method used to investigate the etiology of lymphadenopathy (14,15). It is difficult to precisely distinguish between benign and malignant masses using ultrasonography; however, the number, size, contour structure, roundness

index of the mass, internal structure, and relationship with neighboring tissues are guiding factors (16). Reactive lymph nodes can be as large as infectious or malignant lymph nodes and sometimes even larger. Therefore, the size of the lymph node alone is not a sufficient criterion for distinguishing the etiology (17). Other features of lymph node sonography should be considered to distinguish reactive lymph nodes from those of other causes. Benign lymph nodes usually have an oval shape, hilus with homogeneous echotexture, hilar blood supply pattern, and smooth edges (18-20).

Although the loss of hilar echogenicity is mainly associated with malignant diseases, it can also be observed in benign conditions (6,21). As a matter of fact, one study reported that while the hilus was normal in 84% of reactive lymph nodes, pathology was detected in 16% (20). Na et al. (19) they found that hilar vascularity was abnormal in 6% of LAPs, although they were benign. In our study, loss of hilar echogenicity was more prominent in bacterial and viral lymphadenitis than in reactive LAP. Only 20.6% of patients with reactive LAP had a loss of hilar echogenicity. In a study conducted by Ahuja et al. (22) among adults, the loss of hilar echogenicity was 91% for metastatic LAPs, 71% for tuberculous lymphadenitis, 57% for lymphomatous LAPs, and 15% for reactive LAPs. Ayçiçek et al. (13) performed

ultrasonography on 223 children presenting with lymphadenopathy and found a hypoechoic central hilum in 17% of benign LAPs and in all but one of the malignant cases.

Normal lymph node cortex is usually homogeneous and hypoechoic (17). In our study, there was a loss of cortical echogenicity in 5.6% of reactive LAPs and 3.5% of viral lymphadenitis cases. Additionally, 1.8% of reactive LAPs, 7.6% of bacterial lymphadenitis, and 15% of viral lymphadenitis cases had hyperechoic cortices. Reactive LAPs have a more homogeneous cortex than do other benign lymphadenopathies.

Lymph nodes with thickened cortex may develop in response to infection but are also frequently seen in cases of reactive hyperplasia. In our study, cortical thickening was not sufficient to distinguish reactive from benign LAPs.

The ratio of the short axis to the long axis of the lymph node below 0.5 (an increase in A-P diameter) is evaluated in roundness. Although roundness is a safe criterion for the differentiation of malignant and benign LAP, some studies have found that the rate of round shape is high in tuberculous lymphadenitis (17,22). The rate of round LAP in cases of infectious mononucleosis was reported to be 69% (7). Khanna et al. (3) reported that all histologically diagnosed reactive LAPs were oval. Ahuja et al. (22) reported that 37% of reactive LAPs, 72% of tuberculous lymphadenitis, and 91% of lymphomatous LAPs were round in adult patients with cervical lymph nodes. Ninety-three percent of the lymph nodes in our patients were oval. There were two cases with an increased roundness index in each group.

Microlobulation should be evaluated along with other parameters and is generally favorable for malignancy (22). In our cases, contour lobulation did not help to distinguish benign LAPs.

In benign lymphadenopathies, vascular flow occurs in hilar regions. Suppurative lymph nodes show increased hilar vascularity but may also have a necrotic pattern (3,10,17,19). In malignant nodes, vascularity decreases in the hilar region and increases in the peripheral region, and a chaotic image occurs (23). In addition, necrotic areas can be seen in the lymph nodes due to the infiltration of the medulla by malignant cells and interruption of blood flow. Gupta et al. (5) reported that the vascular pattern has a sensitivity of 89% and a specificity of 95% in determining malignancy.

Prativadi et al. (17) emphasized that benign lymph nodes have hilar vascularity, whereas malignant lymph nodes show a mixed or peripheral vascularity pattern. Kartal et al. (24) reported hilar vascularity, peripheral vascularity, and mixed vascularity in 90%, 5%, and 5% of benign LNs, respectively. Fu et al. (7) found that hilar vascularity was 100% in reactive LAPs, 63% in bacterial lymphadenitis, 17% in LAPs diagnosed as lymphoma, and 90% in EBV lymphadenitis. Vascular pattern is the most sensitive parameter for differentiating between benign and malignant lymph nodes. As can be seen from these studies, hilar vascularity refers to benign LAPs such as primarily reactive LAPs and viral lymphadenitis. All reactive LAPs exhibited hilar vascularity. Necrosis was detected in two patients with suppurative lymphadenitis and EBV lymphadenitis. However, this difference was not statistically significant, probably because of the small number of patients. A peripheral vascular pattern, mostly observed in malignant cases, was not observed.

While reactive LAP and viral lymphadenitis have sharp borders, some studies have mentioned border irregularities in bacterial lymphadenitis (5,6,17). This is due to edema and inflammation in the surrounding tissues. We detected irregular borders in 40% of the bacterial lymphadenitis cases and in one case of viral lymphadenitis. The borders were regular in all the lymph nodes in the reactive LAP group.

Conclusion

This study showed that the size and cortical thickening observed on ultrasonography did not contribute to the differential diagnosis of benign LAP. Loss of hilar echogenicity can be used in the differential diagnosis because it is significantly less common in the reactive LAP group than in the viral lymphadenitis group. In addition, border irregularities can be used as a finding suggestive of bacterial lymphadenitis. However, regardless of the patient's clinical presentation, ultrasonographic findings alone are not sufficient to differentiate reactive LAP.

Study Limitations

The limitation of the present study is that not all diagnoses could be confirmed by biopsy or serological microbiological testing.

Ethics

Ethics Committee Approval: Ethics committee approval was obtained from Sakarya University, numbered E-71522473-050.01.04-155155-227.

Conflict of Interest: No conflict of interest was declared by the authors.

Financial Disclosure: The authors declared that this study received no financial support.

References

- Ahuja AT, Ying M. Evaluation of cervical lymph node vascularity: a comparison of colour Doppler, power Doppler and 3-D power Doppler sonography. *Ultrasound Med Biol* 2004;30:1557-64.
- Ingolfssdottir M, Balle V, Hahn CH. Evaluation of cervical lymphadenopathy in children: advantages and drawbacks of diagnostic methods. *Dan Med J* 2013;60:A4667.
- Khanna R, Sharma AD, Khanna S, Kumar M, Shukla RC. Usefulness of ultrasonography for the evaluation of cervical lymphadenopathy. *World J Surg Oncol* 2011;9:29.
- Brnić Z, Hebrang A. Usefulness of Doppler waveform analysis in differential diagnosis of cervical lymphadenopathy. *Eur Radiol* 2003;13:175-80.
- Gupta A, Rahman K, Shahid M, Kumar A, Qaseem SM, Hassan SA, et al. Sonographic assessment of cervical lymphadenopathy: role of high-resolution and color Doppler imaging. *Head Neck* 2011;33:297-302.
- Park JE, Ryu YJ, Kim JY, Kim YH, Park JY, Lee H, et al. Cervical lymphadenopathy in children: a diagnostic tree analysis model based on ultrasonographic and clinical findings. *Eur Radiol* 2020;30:4475-85.
- Fu XS, Guo LM, Lv K, Wang L, Ran WQ, Tan QT, et al. Sonographic appearance of cervical lymphadenopathy due to infectious mononucleosis in children and young adults. *Clin Radiol* 2014;69:239-45.
- Kim JM, Kim J. Prediction Model for the Differential Diagnosis of Kawasaki Disease and Acute Cervical Lymphadenitis in Patients Initially Presenting with Fever and Cervical Lymphadenitis. *J Pediatr* 2020;225:30-6.
- Niedzielska G, Kotowski M, Niedzielski A, Dybiec E, Wieczorek P. Cervical lymphadenopathy in children--incidence and diagnostic management. *Int J Pediatr Otorhinolaryngol* 2007;71:51-6.
- Weinstock MS, Patel NA, Smith LP. Pediatric cervical lymphadenopathy. *Pediatr Rev* 2018;39:433-43.
- Meier JD, Grimmer JF. Evaluation and management of neck masses in children. *Am Fam Physician* 2014;89:353-8.
- Weinberg GA, Segel GB, Hall CB. Lymphadenopathy. In: Adam HM, Foy JM, editors. *Signs and Symptoms in Pediatrics*. Elk Grove Village: American Academy of Pediatrics 2015:637.
- Ayçiçek A, Erdoğan B. Lenfadenomegalisi Olan 223 Çocuk Hastanın Prospektif Değerlendirilmesi. *Türkiye Çocuk Hast Derg* 2015;3:161-6.
- Riva G, Sensini M, Peradotto F, Scolfaro C, Di Rosa G, Tavormina P. Pediatric neck masses: how clinical and radiological features can drive diagnosis. *Eur J Pediatr* 2019;178:463-71.
- Gaddey HL, Riegel AM. Unexplained Lymphadenopathy: Evaluation and Differential Diagnosis. *Am Fam Physician* 2016;94:896-903.
- Giovagnorio F, Caiazza R, Avitto A. Evaluation of vascular patterns of cervical lymph nodes with power Doppler sonography. *J Clin Ultrasound* 1997;25:71-6.
- Prativadi R, Dahiya N, Kamaya A, Bhatt S. Chapter 5 Ultrasound Characteristics of Benign vs Malignant Cervical Lymph Nodes. *Semin Ultrasound CT MR* 2017;38:506-15.
- Grant CN, Aldrink J, Lautz TB, Tracy ET, Rhee DS, Baertschiger RM, et al. Lymphadenopathy in children: A streamlined approach for the surgeon - A report from the APSA Cancer Committee. *J Pediatr Surg* 2021;56:274-81.
- Na DG, Lim HK, Byun HS, Kim HD, Ko YH, Baek JH. Differential diagnosis of cervical lymphadenopathy: usefulness of color Doppler sonography. *AJR Am J Roentgenol* 1997;168:1311-6.
- Steinkamp HJ, Teichgräber UK, Mueffelmann M, Hosten N, Kenzel P, Felix R. Differential diagnosis of lymph node lesions. A semiquantitative approach with power Doppler sonography. *Invest Radiol* 1999;34:509-15.
- Ying M, Ahuja AT, Evans R, King W, Metreweli C. Cervical lymphadenopathy: sonographic differentiation between tuberculous nodes and nodal metastases from non-head and neck carcinomas. *J Clin Ultrasound* 1998;26:383-9.
- Ahuja A, Ying M. An Overview of Neck Node Sonography. *Invest Radiol* 2002;37:333-42.
- Varkal MA, Yıldız İ, Ünüvar E. Çocukluk çağında lenfadenopatiye yaklaşım. *İst Tıp Fak Derg* 2015;78:51-7.
- Kartal Ö, Ataş E, Gürsela O. Differentiation of benign from malignant cervical lymphadenopathy by ultrasonography in children. *Arch Argent Pediatr* 2020;118:11-7.